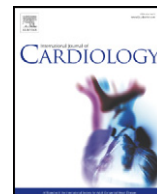




Contents lists available at ScienceDirect

## International Journal of Cardiology

journal homepage: [www.elsevier.com/locate/ijcard](http://www.elsevier.com/locate/ijcard)

# A new kaolin-based hemostatic bandage use after coronary diagnostic and interventional procedures

Daniela Trabattoni<sup>\*</sup>, Pamela Gatto, Antonio L. Bartorelli

Department of Cardiovascular Sciences, Centro Cardiologico Monzino, IRCCS, University of Milan, Milan, Italy

## ARTICLE INFO

### Article history:

Received 19 April 2010

Received in revised form 9 August 2010

Accepted 23 October 2010

Available online xxx

### Keywords:

Hemostasis

Kaolin-based gauze

Vascular closure

Manual compression

## ABSTRACT

**Background:** Bleeding and vascular access site complications are an important cause of morbidity after percutaneous femoral procedures. Together with collagen-based and suture-based vascular closure devices, new hemostatic dressings have been developed to control heavy bleeding.

**Aim of study:** To evaluate safety and efficacy results of the first clinical QuikClot Interventional Hemostatic Bandage use for femoral artery closure after diagnostic or interventional procedures.

**Methods:** The first European safety study was performed at the Centro Cardiologico Monzino in Milan, Italy, on January 2010. Forty consecutive patients (75% male, mean age  $68 \pm 11$  years) undergoing diagnostic angiography (62%) or PCI (38%) by femoral approach with a 6- (90%) or 7-Fr (10%) size introducer, received arterial sheath removal with the QuikClot Interventional gauze use. The mean ACT value at hemostasis time was  $138 \pm 24$  s (range 95–186 s). Hemostasis was achieved in a mean time of  $4.9 \pm 0.5$  min. Only one hemostasis failure occurred requiring prolonged mechanical compression. Neither major bleeding, re-bleeding nor hematoma occurred after early (4 h after procedure) ambulation.

**Conclusions:** QuikClot Interventional Bandage obtained prompt hemostasis and allowed for an early ambulation without clinical complications.

© 2010 Elsevier Ireland Ltd. All rights reserved.

## 1. Introduction

Vascular closure starts with a correct arterial access. Access site complications are the single greatest cause of morbidity after percutaneous femoral procedures. Bleeding complications, most notably pseudoaneurysm and hematoma, occur in 5% to 10% of patients and lead to surgical repair in 1.5% of them, approximately [1]. Major predictors for vascular closure device (VCD) failures and bleeding complications at the access site include age, gender, diabetes, renal failure, obesity and sheath insertion in a non-target puncture zone (femoral bifurcation, superficial femoral artery, collaterals –i.e. inferior epigastric artery–, severe vascular calcifications or peripheral artery disease) [2,3]. According to the American College of Cardiology 2009 NCDR registry [4], VCD is still only used in a minority of patients (34.6% in diagnostic procedures, 37.6% in PCIs), in the U.S. No large randomized trials are yet available on VCDs compared to manual compression [5]; however, there is growing interest to reduce hospital stay after diagnostic and interventional procedures and to find alternative closure devices to avoid collagen-based or suture-based hemostasis in specific vascular and patient settings, without increasing procedural complications.

In recent years, new hemostatic dressings have been developed to control heavy bleeding [6,7]. Previous in-vivo animal hemorrhage models found the kaolin-based gauze to be the most effective product among four new dressings tested. This device allowed the least amount of hemorrhage and the highest survival rate in tested animals [8]. Here we report safe and effective femoral puncture site closure with QuikClot Interventional Hemostatic Bandage use in the cath lab.

## 2. Device description

QuikClot Interventional Hemostatic Bandage (Z-Medica, Wallingford, CT) is a non-woven coated gauze (Fig. 1). Each dressing is a multiple-ply 1.5 in.  $\times$  1.5 in.  $\times$  0.5 in. rayon/polyester construction coated with kaolin. Kaolin is an aluminum silicate, a very potent coagulation initiator that acts as a surface activator. Its inert characteristics allow for no skin allergies at the site of application. The gauze is stable after opening the external aluminum envelop. It is absorbent and has good clotting ability. This advanced clotting gauze is a Food and Drug Administration (FDA) and CE cleared device.

## 3. Technical specifications

The method for QuikClot use is as follows: 1) apply a firm manual compression on the femoral artery with the QuikClot Interventional Bandage above the entry site while removing the arterial sheath; 2) maintain a firm compression for 5 min; 3) leave the QuikClot over the

<sup>\*</sup> Corresponding author. Centro Cardiologico Monzino, IRCCS, Via Parea, 4, 20138 Milan, Italy. Tel.: +39 02 58002546; fax: +39 02 58002398.

E-mail address: [daniela.trabattoni@ccfm.it](mailto:daniela.trabattoni@ccfm.it) (D. Trabattoni).

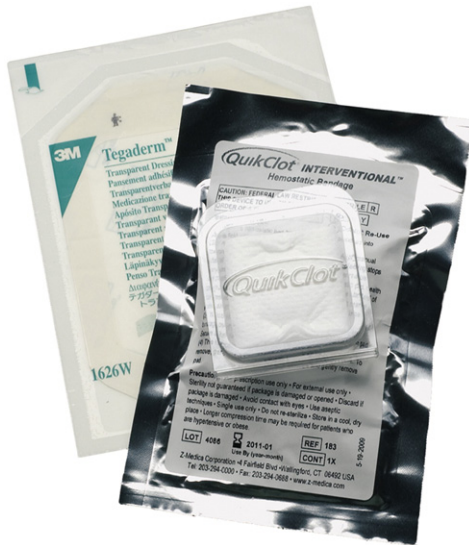

Fig. 1. QuikClot Interventional Bandage.

access site and cover it with a non-compressive dressing; 4) check the groin at 15 min, 1, 4 and 12 h; and 5) allow the patient to ambulate four hours after hemostasis achievement.

#### 4. Safety and effectiveness report

The first European safety study was performed at the Centro Cardiologico Monzino in Milan, Italy, after the Ethics Committee approval, on January 2010. Forty consecutive patients (75% male, mean age  $68 \pm 11$  years) undergoing invasive diagnostic angiography (62%) or PCI (38%) by femoral approach with a 6- (90%) or 7-Fr (10%) size introducer, received arterial sheath removal at a mean time of  $2.43 \pm 4.0$  h after procedure with the QuikClot Interventional gauze use, once ACT value was  $\leq 180$  s. The mean ACT value at hemostasis time was  $138 \pm 24$  s (range 95–186 s). Patients were on aspirin (60%), aspirin + clopidogrel (27.5%), LMWH (2.5%) or aspirin + warfarin (5%). Effectiveness results are shown in Table 1.

Hemostasis failure occurred in 1 PCI case, thus hemostasis was achieved after prolonged mechanical compression with the occurrence of a minor (<5 cm) hematoma. Neither major bleeding, re-bleeding nor hematoma occurred after ambulation.

#### 5. Discussion

Vascular closure device use for PCI may be associated with fewer vascular complications [9]. It is however known that anatomical issues (collaterals, severe vessel calcifications, peripheral artery disease, puncture at the bifurcation site, and previous multiple

**Table 1**  
QuikClot Interventional gauze hemostasis effectiveness.

	QuikClot gauze	%
Mean cumulative hemostasis time	$4.9 \pm 1.05$ min	
Diagnostic procedures	$4.2 \pm 0.9$ min	
Interventional procedures	$5.3 \pm 0.95$ min	
Cumulative frequencies	4 min	11
	5 min	85
	6 min	93
	8 min	98
Ambulation time	4 h	100

femoral artery stitches) may contraindicate VCD use. This preliminary clinical evaluation in the interventional cardiology field shows QuikClot Interventional Hemostatic Bandage is an easy to use and effective device that assists in achieving a short-term passive hemostasis. This availability of an alternative technique to standard manual or mechanical compression, with an advanced clotting time, allows for a shorter and painless hemostasis procedure as well as for an early ambulation time.

#### 6. Conclusions

QuikClot Interventional Hemostatic Bandage obtains prompt hemostasis and allows an early, safe ambulation following coronary diagnostic and interventional procedures by femoral approach.

#### Acknowledgement

The authors of this manuscript have certified that they comply with the Principles of Ethical Publishing in the International Journal of Cardiology [10].

#### References

- [1] Starnes BW, o'Donnell SD, Gillespie DL, et al. *J Vasc Surg* 2003;28:263–71.
- [2] Ahmed B, Piper WD, Malenka D, et al. Significantly improved vascular complications among women undergoing percutaneous coronary intervention: a report from the northern New England percutaneous coronary intervention registry. *Circ Cardiovasc Interv* 2009;2(5):423–9.
- [3] Roguin A, Steinberg BS, Watkins SP, Resar JR. Safety of bivalirudin during percutaneous coronary interventions in patients with abnormal renal function. *Int J Cardiovasc Interv* 2005;7(2):88–92.
- [4] American College of Cardiology National Cardiovascular Data Registry. Cardiac catheterization. Available at: <http://www.ncdr.com/webNCDR/NCDRDocuments>.
- [5] Koreny M, Riedmuller E, Nifkardjam M, Siostrzonek P, Mullner M. Arterial puncture closing devices compared with standard manual compression after cardiac catheterization. *JAMA* 2004;291:350–7.
- [6] Arnaud F, Teranishi K, Tomori T, Carr W, McCarron R. *J Vasc Surg* 2009;50:632–9.
- [7] Arnaud F, Parreno-Sadalan D, Tomori T, et al. *J Trauma* 2009;67:848–55.
- [8] Kheirabadi BS, Scherer MR, Estep JS, Dubick MA, Holcomb JB. *J Trauma* 2009;67:450–60.
- [9] Martin JL, Pratsos A, Magargee E, et al. A randomized trial comparing compression, Perclose proglide and Angioseal Vip for arterial closure following percutaneous coronary intervention: the CAP trial. *Catheter Cardiovasc Interv* 2008;71:1–5.
- [10] Coats AJ. Ethical authorship and publishing. *Int J Cardiol* 2009;131:149–50.